


# SIMPLE, SUCCESSFUL COMPOSITE REPAIRS

## Techniques to Remedy Surface Defects



Corky Willhite, DDS, FAGD, AACD Accredited Fellow  
Illustrations by Zach Turner

### INTRODUCTION

When patients present with esthetic composite restorations requiring repair, or if defects are detected during the direct restorative process, a simple technique for repairing composite defects is invaluable.<sup>1</sup> This basic technique can be varied slightly to correct composite defects at a couple of different points in the restorative process: initial placement and post-treatment. These procedures can remedy defects involving pits and voids, fractures, white lines, and improper contouring (**Figs 1-2**).

Key to this technique's success is ensuring that the repair is completed prior to any polishing if the procedure is to be accomplished during the initial fabrication of the restoration. If the surface has already been polished, added composite will not bond to the surface. Therefore, it will be necessary to roughen the composite surface in order to repair the composite defect (**Fig 3**).<sup>2,3</sup>

Additionally, for the post-treatment repair of microhybrid and nanohybrid restorations more than one day old, a micro-etching sandblast should be applied to the defective area prior to etching with 35% phosphoric acid.<sup>4</sup> For microfill repairs, this author does not recommend sandblasting. Because the microfill composites contain such small and uniform particles, micro-etching decreases the mechanical retention created by the bur marks.

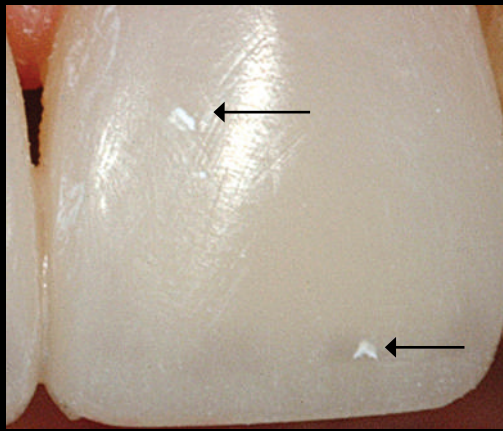


Figure 1: Close-up view showing two defects on tooth #9.



Figure 2: Close-up view of a four-and-a-half year old composite restoration on tooth #9 that presented with a stained void.

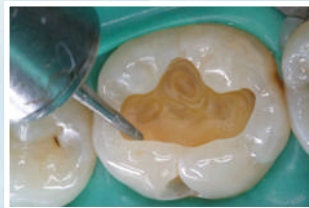## Venus<sup>®</sup> Bulk Fill

Faster, esthetic posterior restorations. **Simplified.**

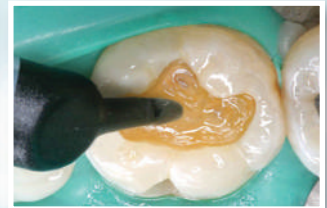
**Venus<sup>®</sup> Bulk Fill** is a low stress flowable composite that will enable bulk filling of 4mm and provide an efficient and easy solution for esthetic posterior restorations.

**Venus Bulk Fill** delivers:

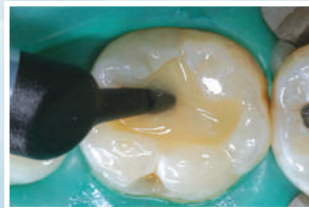
- Self-adaptive handling eliminates steps and provides ideal coverage of cavity floor and walls
- Long working time for when you need it
- Highly radiopaque for more accurate diagnosis



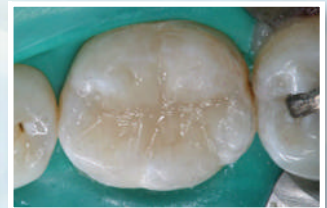1. Prep



2. Fill with Venus Bulk Fill after adhesive placement



3. Final layer with Venus Diamond



4. Final Class I restoration by Dr. Amanda Canto, Houston, TX

To learn more about the clinical advantages of Venus Bulk Fill, call toll-free **877-258-5937** or visit **[www.heraeusdentalusa.com](http://www.heraeusdentalusa.com)**.

**82%** of surveyed dentists claim a **SAVINGS UP TO 10 HOURS OF CHAIR TIME** per month when they use a bulk fill material.\*

\* Integrated Media Survey, May 2010. © 2010 Heraeus Kulzer, LLC  
Venus<sup>®</sup> is a registered trademark of Heraeus Kulzer GmbH.

Venus<sup>®</sup>  
The New Esthetics

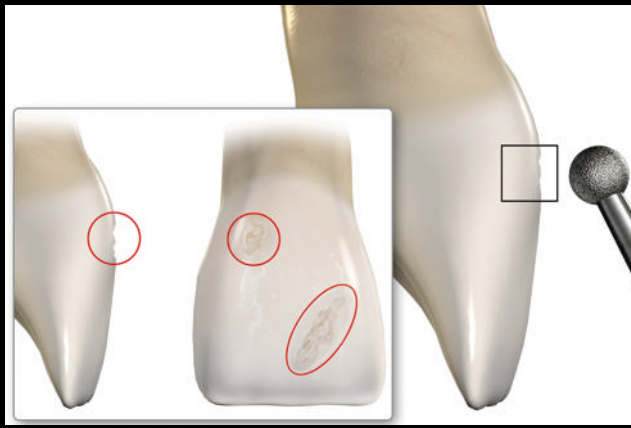


Figure 3: Repairing a composite defect will require roughening the composite surface.



Figure 4: Use a large, round, fine-grit diamond bur on the surface of the restoration.




Figure 5: The bur should only engage deep enough to make a saucer-shaped preparation.

## Technique

### STEP 1.

If the composite surface has already been polished, lightly roughen the area with a coarse contouring disk or a fine-grit diamond bur. On the unpolished or roughened surface with the defect, place a large, round, fine-grit diamond bur (8801-018, Brasseler USA; Savannah, GA) on the surface of the restoration (Fig 4), engaging it only deep enough to make a shallow saucer-shaped preparation (Fig 5). As a beveled margin is desired (Fig 6), do not allow the bur to sink deeper into the composite surface, which would create a butt joint margin. If the defect extends deeper into the saucer-shaped preparation, to avoid making the repair larger than necessary, use a smaller round bur to deepen only the specific area of the deeper defect (Fig 7).



Figure 6: A beveled margin is desired.



Figure 7: If the defect extends deeper into the saucer-shaped preparation, use a smaller round bur to deepen only that area.

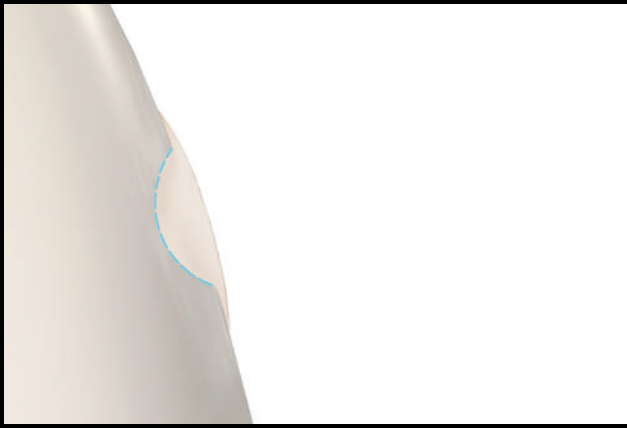


Figure 8: Etch the preparation to clean debris and apply a thin layer of unfilled resin, but do not cure at this time.

#### STEP 2.

Acid-etch the prepared area for three to five seconds to remove debris and clean the surface, rinse well, and dry thoroughly. Apply a thin layer of unfilled resin to the preparation. Do not light-cure at this time. (Fig 8).




Figure 9: Place and sculpt the composite, without over-bulking it, then light-cure.

#### STEP 3.

Without over-bulking the repair, place and sculpt the composite. Light-cure the composite as directed. (Fig 9).



Figure 10: Contour the repair, then polish the restoration.

#### STEP 4.

Contour the repair to mimic the natural dentition. After contouring the repair, complete a final polish of the restoration to achieve esthetic and functional success (Figs 10-12).

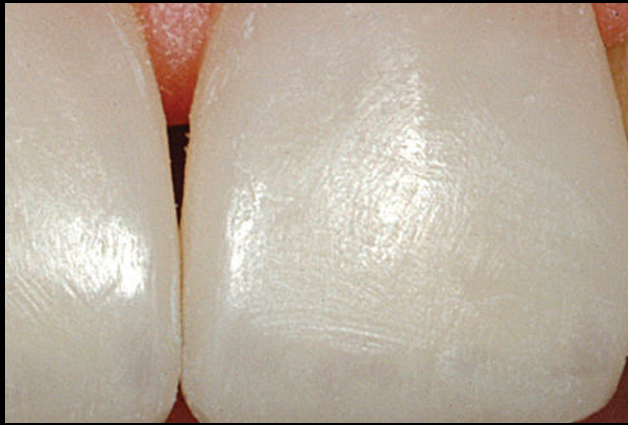

Figure 11: Close-up view of the repair to correct the defects shown in Figure 1.

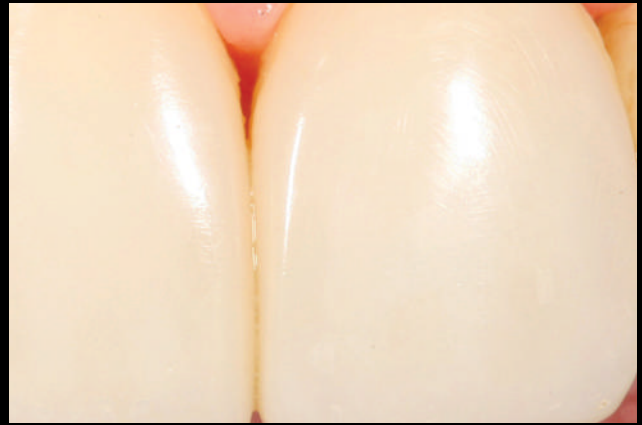

Figure 12: Close-up view of the repair to correct the stained void shown in Figure 2.

## References

1. Denehy G, Bouschlicher M, Vargas M. Intraoral repair of cosmetic restorations. *Dent Clin North Am.* 1998;42(4):719-37.
2. Fawzy AS, El-Askary FS, Amer MA. Effect of surface treatments on the tensile bond strength of repaired water-aged anterior restorative micro-fine hybrid resin composite. *J Dent.* 2008 Dec;36(12):969-76. Epub 2008 Oct 7.
3. Nilsson E, Alaeddin S, Karlsson S, Milleding P, Wennerberg A. Factors affecting the shear bond strength of bonded composite inlays. *Int J Prosthodont.* 2000 Jan-Feb;13(1):52-8.
4. Yesilyurt C, Kusgoz A, Bayaram M, Ulker M. Initial repair bond strength of a nano-hybrid resin: effect of surface treatments and bonding agents. *J Esthet Restor Dent.* 2009;21(4):251-60. **JCD**

### LARGER REPAIRS:

Repairs of fractures or other large problems can be accomplished using the same steps to prepare the existing surface. Round or smooth any sharp corners or irregular edges, then micro-etch, acid-etch, apply unfilled resin, and add composite.

**About the Author:** Dr. Willhite graduated from the Louisiana State University (LSU) School of Dentistry in 1979. He is an Adjunct faculty member in the Department of Prosthodontics at LSU. Dr. Willhite's private practice in suburban New Orleans is limited to cosmetic dentistry.

**Author Disclosure:** The author did not report any disclosures.



HAVE YOU SEEN  
**THE LIGHT?**

"Fantastic"  
"Practice Altering"  
"Amazing"  
"Revolutionary"

SEE THE LIGHT &  
JOIN THE BELIEVERS:

**VALO**  
broadband LED curing light

ULTRADENT  
800.552.5512 • ultradent.com

2010  
**REALITY**  
Five Star Award  
REACTIVITY'S  
CHOICES

INTERNATIONAL DESIGN  
EXCELLENCE AWARDS '10  
BRONZE

DENTAL PRODUCTS REPORT  
**TOP100**